

Rehabilitation Guidelines for Hip Arthroscopy Procedures

Introduction:

The hip joint is composed of the femur (the thigh bone), and the acetabulum (the socket which is from the three pelvic bones). The hip joint is a ball and socket joint that not only allows flexion and extension, but also rotation of the thigh and leg. Unlike the shoulder, however, stability is not sacrificed for mobility. The head of the femur is encased by the socket, and with the addition of the strong, non-compliant joint capsule, the hip is an extremely stable joint. Because the hip is responsible for transmitting the weight of the upper body to the lower extremities, the joint is subjected to substantial forces. Walking transmits 1.3 to 5.8 times body weight through the joint, and running and jumping can generate forces across the joint equal to 6 to 8 times body weight.

The labrum is a circular, fibro- cartilaginous structure that surrounds the socket. It functions to seal the joint, enhance stability, and provide proprioceptive feedback (tells hip joint position) to the brain and central nervous system. The labrum acts as a suction seal or gasket for the hip joint. This helps to maintain the hydrostatic pressure that protects the articular cartilage on the head of the femur and the acetabulum.

The iliopsoas tendon connects the fibers of the psoas major and iliacus muscles to the proximal femur (lesser trochanter). Painful snapping of this tendon can occur during flexion and extension of the hip when the tendon pops over a bony prominence (iliopectineal eminence) that is located in the area of the anterior hip joint. The

pain and snapping may be very similar to that which occurs with labral tears.

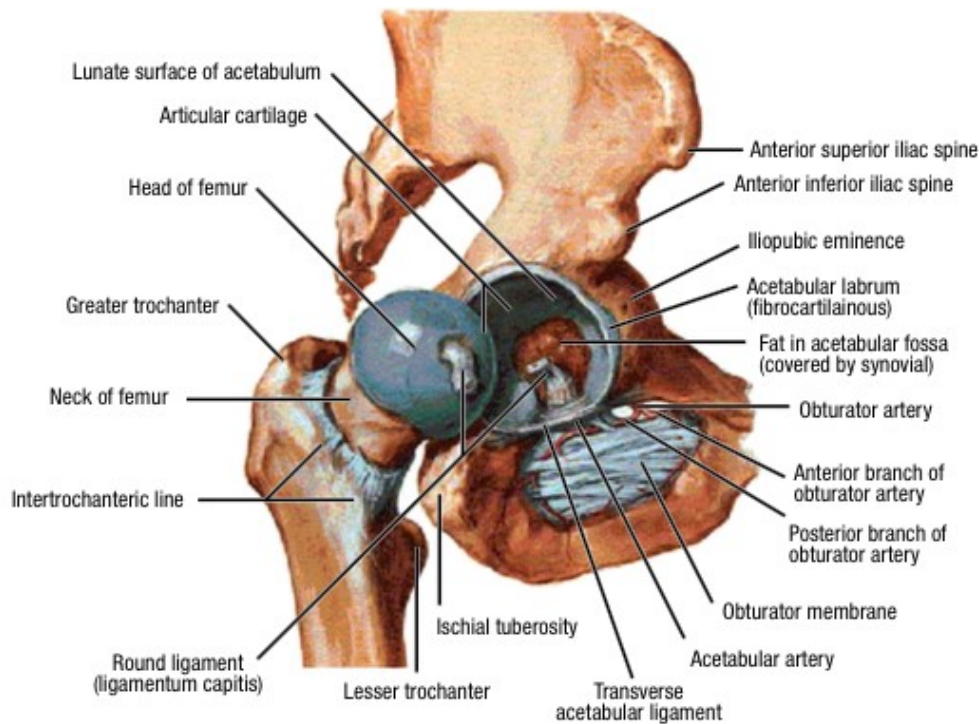
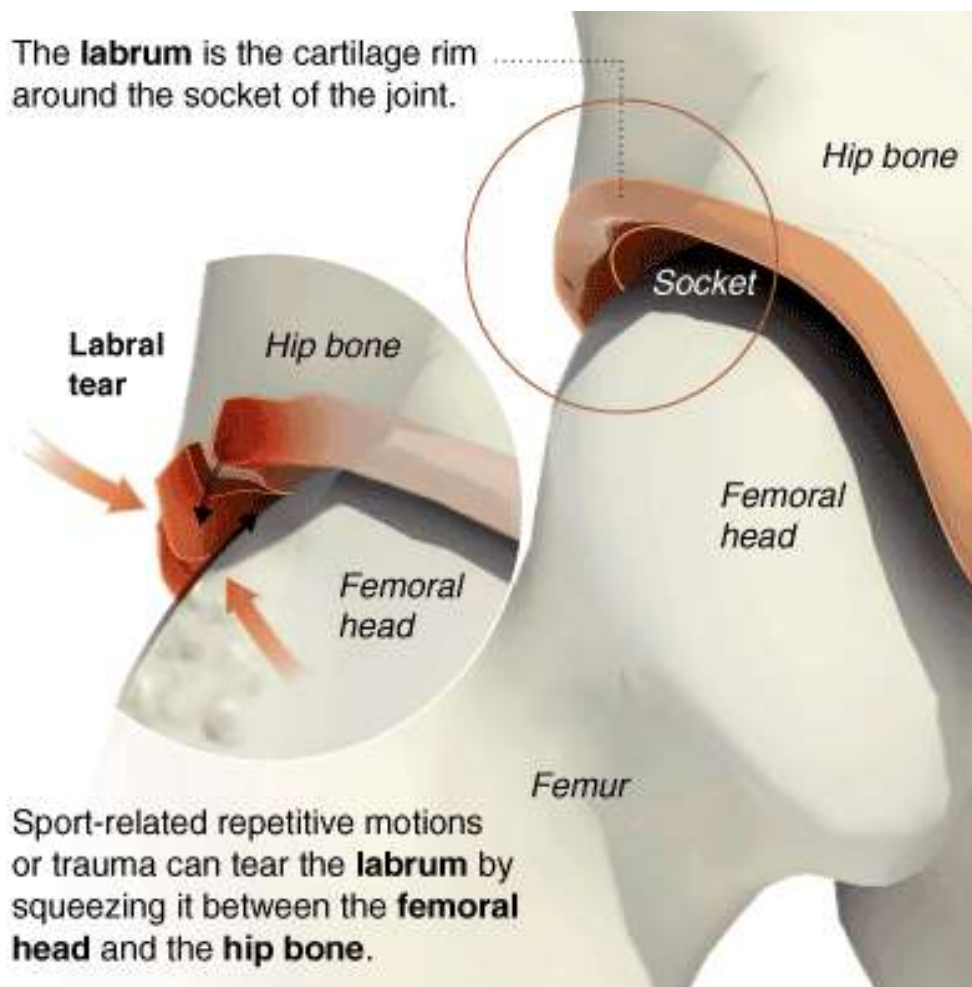


Figure 1 Hip joint (opened) lateral view

Hip joints are exposed to extremes of motion, and these forces are absorbed by and can injure the labrum. It is currently thought that the labrum may also be injured by impingement of the hip. This is referred to as femoroacetabular Impingement (FAI). FAI can occur from changes in the shape of the acetabulum or the femoral head and neck. FAI due to “over-coverage” of the acetabulum is referred to as pincer impingement. FAI due to a lack of the normal femoral head-neck off-set, or “lack of femoral head roundness”, is referred to as cam impingement. Figure 2 demonstrates the bony abnormality associated with cam impingement of the right hip; note the difference in the shape of the femoral head. Some people have a “Bump or Pincer” on their hip causing pain. This typically causes discomfort deep inside the hip and around the outer buttock / hip area. It can feel like the hip is dislocating or is coming out of the

socket. This bump is a bony extra bit on top of the hip ball (Cam) and causes pain when it hits the socket during normal movements. The pincer is an extra bit of wedge shaped bone overhanging over the socket. Another name for this is Femoro-Acetabular Impingement or FAI. Often times, cam and pincer impingement can co-exist. When the normal convex on concave (or ball and socket) geometry is lost, impingement may occur as the hip is flexed toward its end range. This is often accentuated with adduction and internal rotation. Repetitive impingement can cause labral tears and delamination of the acetabular articular cartilage.

Labral tears may cause a sharp catching pain, popping, and a sensation of locking of the hip (mechanical symptoms). Most people with this injury experience more subtle, dull, activity-induced positional pain – especially if they have femoroacetabular impingement. They most often describe a deep discomfort in the anterior groin, and occasionally the pain may be directly lateral (greater trochanter area), or deep within the buttocks. Flaps from damaged articular cartilage may cause mechanical symptoms but most often they will cause pain during or after weight bearing and impact activities, such as running and jumping.



Hip labral tears occur when the ball is jammed into the socket, damaging the soft cartilage lip called the labrum. This can lead to further injury and arthritis if left untreated.

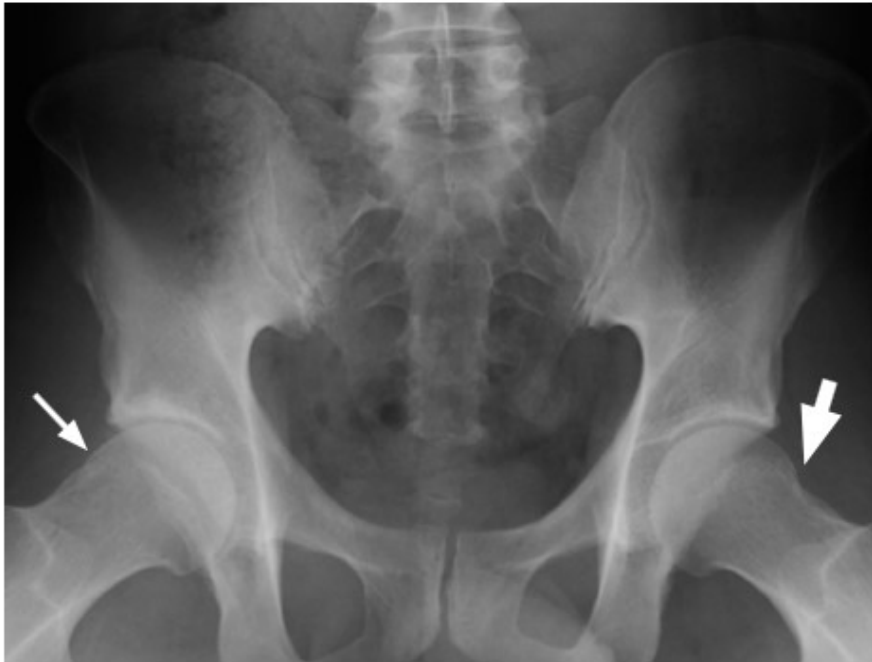

Figure 2: Frog leg radiograph: The thin arrow on your left indicates the area of “flattening” of the right femoral head and lack of the normal femoral head-neck offset. The thick arrow on the right indicates the more normal, rounded contour of the left femoral head.

Non-operative treatment of painful labral tears usually is not successful. However, 25% of individuals over the age of 50 have labral tears seen on MRIs, but no symptoms. Thus, arthroscopic treatment of a labral tear is only indicated when appropriate clinical tests and imaging studies have documented that the hip pain is due to the labral tear. Labral tears can be treated by partial resection or repair. If indicated, labral repair is preferred as it attempts to restore the normal suction seal of the hip joint. If the tear is too small or the quality of the injured tissue is too poor, repairs are not performed.

Both of these procedures can be done arthroscopically.

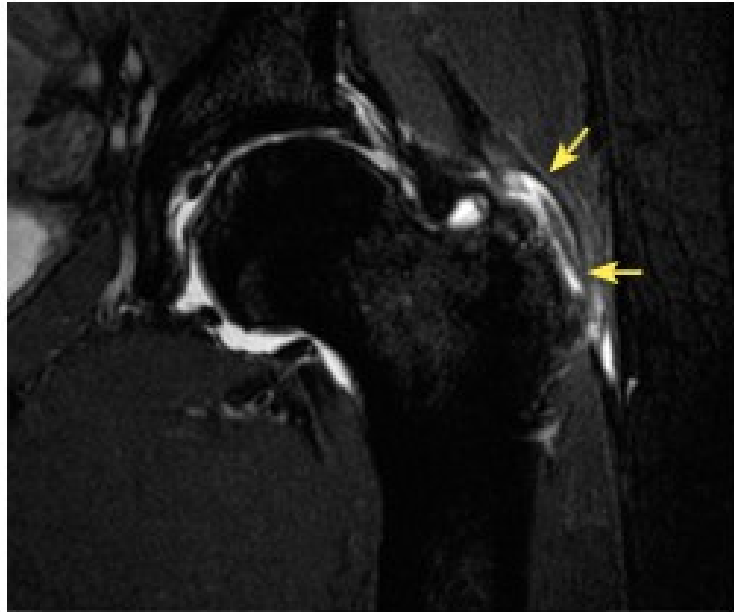
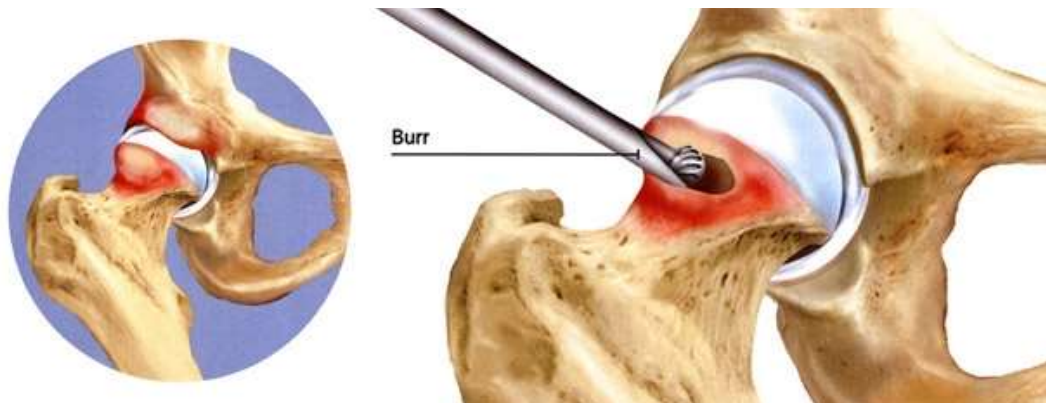


Figure 3: T2 MR image showing abductor tendon tears (yellow arrows) at the greater trochanter of the femur.

Hip arthroscopy is performed on an outpatient basis under general anesthesia. The hip to be operated upon is placed in traction to open up the hip joint enough to allow for the insertion of the instruments. After marking out the anatomical landmarks with X-ray guidance, two to four small incisions are made in the area of the hip joint. One of these incisions is used to insert a camera that displays the inside of the hip joint on a television monitor, and the other incisions are used to insert the surgical instruments used for excising labral tears, debriding the Cam Bump, defective cartilage, removing bone spurs, and removing loose bodies.



Hip arthroscopy is also used to ^[1]~~SEP~~ treat the hip pain and mechanical symptoms caused by a number of other conditions including: loose bodies; iliopsoas snapping; hip instability; hip abductor muscle-tendon tears; chondral lesions; ligamentum teres tears; and femoroacetabular impingement (FAI).

When treating FAI, a burr is used to reshape the femoral head-neck offset. This is called a proximal femoral osteoplasty. The goal is to restore the normal convex on concave relationship (ball on socket) so that the hip can move through the full range of motion without impingement. To treat chondral lesions, a microfracture technique may be performed after the damaged articular cartilage is removed. This is done by creating small holes in the subchondral bone of the defect to promote the inflow of blood and stem cell in the hopes that these elements will lead to the growth of fibrocartilage to fill the chondral defect. Although the fibrocartilage is not as strong as the original hyaline cartilage, it does act to create continuity of the surface.

Using arthroscopic instruments, the “peripheral hip joint” (the space outside of the socket part of the hip joint) can be visualized and thus, FAI can be arthroscopically treated. The “peritrochanteric” (greater trochanteric bursa) area of the hip joint also can be visualized, and this advance in hip arthroscopy has allowed for the release of the Ilio-Tibial Band (this tight layer of tissue rubs & inflames the bursa, causing bursitis) and trochanteric bursa removal to treat ongoing

trochanteric bursitis.

Iliopsoas tendon injuries are another source of anterior hip pain. Most often they are caused by an acute injury, and less commonly, the result of repetitive trauma. The iliopsoas can snap over the iliopectineal eminence and bursae (Figure 4). The painful snapping usually is audible and associated with a sensation of snapping and hip pain. However, anterior hip pain due to iliopsoas bursitis and tendonitis may occur without snapping of the tendon. It should be noted that asymptomatic snapping is not uncommon in hypermobile athletes.

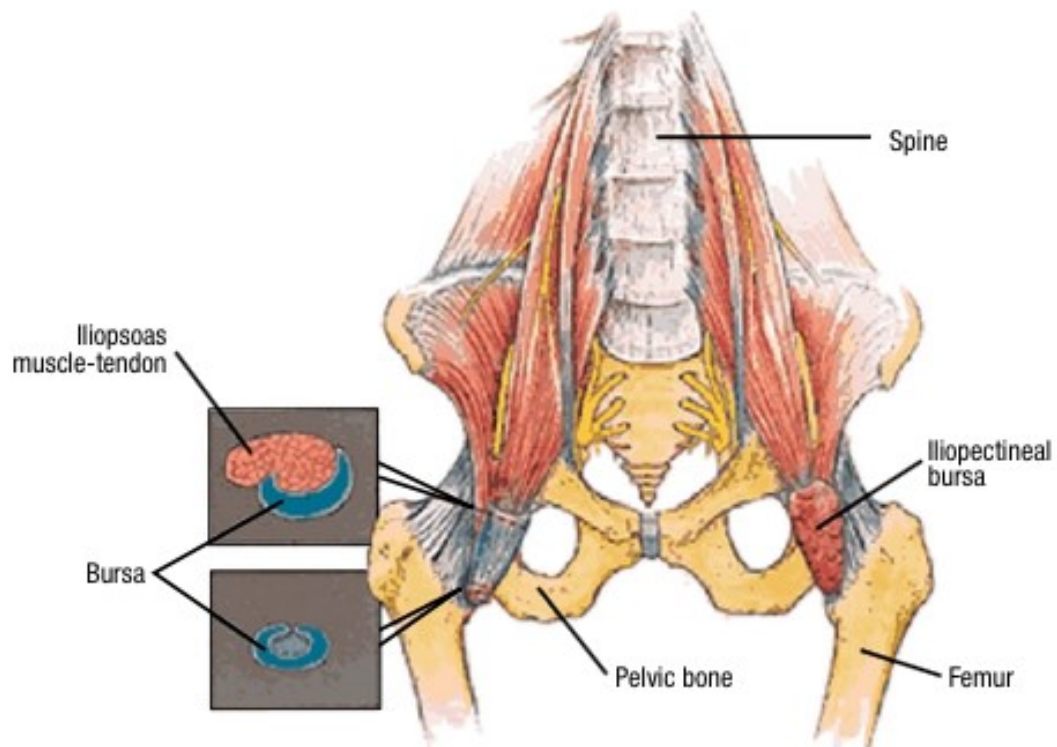


Figure 4: Diagram of the iliopsoas muscle-tendon and bursa.

Non-operative treatment (physical therapy and psoas bursa injections) is successful in getting almost two thirds of patients with painful snapping hips back to full activity. When these measures fail, an arthroscopic release of the iliopsoas tendon often is performed and does provide long-term relief of the snapping and pain.

Rehabilitation of the hip begins the day after surgery. The rehabilitation guidelines are presented in a criterion-based progression, and each patient will progress at a different rate depending on the specific procedure performed, age, pre-injury health status, and rehab compliance. The patient may also have postoperative hip and thigh pain which can slow the recovery rate. This can be caused by traction on the hip during surgery. There may also be reflex inhibition and poor control of the muscles that stabilize the hip from the traction and from penetration of the hip joint with the arthroscopic instruments. It is very important to use crutches for the first few weeks after surgery in order to minimize abnormal forces on the back and pelvic joints while developing muscle coordination and strength to support the hip and to achieve a normal gait pattern. This is especially important with microfracture, labral repair and iliopsoas tendon release, as hip flexors are significantly weakened for two to six weeks after surgery. All exercises should be performed within pain tolerance. Pushing to extremes of motion beyond pain tolerance does not enhance function but rather increases discomfort and prolongs rehabilitation.

Rehabilitation Guidelines for Hip Arthroscopy Procedures

Basic Rehabilitation Principals:

1. Post-operative recovery begins with a preoperative educational visit for instruction, explanation, and demonstration of the postoperative rehab program.
2. Precautions and limitations during Phase I of the post-operative rehabilitation will be determined by which arthroscopic procedures are performed, since not all arthroscopies are the same. Post-operative weight bearing status will not be based on hip pain alone. Although the discomfort after hip arthroscopy may be surprisingly little, there often is a significant amount of reflex inhibition and poor muscle firing due to the penetration of the hip with the arthroscopic instruments and the large amount of traction applied to the hip during the arthroscopy. Weight bearing may also be limited to allow for healing to occur. Consequently, crutches or other assistive devices should be used until guidance from your physician or physical therapist allows you to discontinue them.
3. Active assistive range of motion exercises are begun early (the first 1-7 days after surgery), but maximum motion in any plane is determined by where the patient feels discomfort, and stretching should only be pushed to tolerance. Pushing to extremes of motion does not enhance function, and will increase discomfort and prolong rehabilitation. Similar to weight bearing status, there may be some procedures that limit the extent of range of motion to allow appropriate healing.

4. Muscle strengthening exercises are to be performed during the first week after surgery, but progressive strengthening depends upon the patient's tolerance. Patients should avoid exercises that engage the iliopsoas during the first several weeks after surgery. Iliopsoas tendonitis is a known side effect of hip arthroscopy but can be avoided with appropriate post-operative care, including avoiding exercises that have high activity of the iliopsoas (such as straight leg raises, resisted hip flexion, abductor strengthening that incorporates significant co-contraction).⁶ If the patient had an abductor repair, abductor strengthening will be limited early in the rehab process to allow the tendon to heal back to the bone.

PHASE I (Surgery to 3-6 weeks)

Appointments	First rehabilitation appointment should be 3 to 5 days after surgery, 1 to 2 times per week thereafter
Rehabilitation Goals	<ul style="list-style-type: none"> • Protection of the post-surgical hip through limited weight bearing and education on avoiding pain (approximately 3/10) with range of motion exercises • Restore normal hip range of motion • Normalize gait • Restore leg control
<p>Osteoplasty or CAM debridement</p> <p>+/- Labral Repair or Excision and Debridement</p> <p>(Including for FAI) Precautions</p>	<ul style="list-style-type: none"> • Week 0 to 2 Weightbearing with crutches • Week 2 to 4 Independent weight bearing to 100% progressively • Week 5 to 6+ progress to Full weight bearing, then wean from crutches slowly when

<p>We may also do bilateral sequential surgery two weeks apart to give you treatment for the hips and one phase of recovery that is around 4 to 6 weeks to get you back on your feet.</p>	<p>gait is normalized and pain free (without pain medications), which normally takes 2 to 3 weeks</p> <ul style="list-style-type: none"> • Avoid active hip flexion past 90° avoid pushing range of motion to the point of pain in any plane x 4 weeks • Avoid exercises that engage the iliopsoas during the first several weeks after surgery. Iliopsoas tendonitis is a known side effect of hip arthroscopy but can be avoided with appropriate post-operative care, including avoiding exercises that have high activity of the iliopsoas (such as straight leg raises, resisted hip flexion, abductor strengthening that incorporates significant co-contraction)⁶ • Avoid straight leg raises
<p>Iliopsoas Release (With or Without Ischiofemoral Impingement Osteoplasty) Precautions</p>	<ul style="list-style-type: none"> • Use axillary crutches until normal gait and hip flexor muscle function is achieved (without pain medications) and wean from crutches slowly when gait is normalized and pain free (without pain medications), which normally takes 3 to 6 weeks • Do not do straight leg raises to avoid irritation of the released tendon as it scars down

	<ul style="list-style-type: none"> • Avoid pushing motion to approximately 3/10 pain in any plane, and have patient keep pain at less than approximately 3/10 with stretches [SEP]
Microfracture Precautions	<ul style="list-style-type: none"> • 30%, 50% and 70% weight bearing with crutches increase by every 2 weeks • Avoid hip flexion past 90° for 2 weeks • Avoid impact exercises and activities for 12 weeks • NOTE: The precautions will depend on the size and location of the area undergoing the microfracture procedure
Abductor Repair Precautions	<ul style="list-style-type: none"> • No active abduction x 6 weeks • Partial weight bearing with crutches x 4 to 6 weeks
Range of Motion Exercises	<ul style="list-style-type: none"> • Active assistive range of motion and passive range of motion of hip in all planes. Note: Microfracture patients should do multiple hours of active assistive range of motion/passive range of motion exercises each day to help developing fibrocartilage

Suggested Therapeutic Exercises

- Day of surgery begin isometric quadriceps, glut, hamstring, hip adductor and hip abductor muscle strengthening sets
- Gait activities (marching, heel-toe rocking, sidestepping) – may utilize pool for gait activities once the portal sites are healed
- Isometric hip flexion, extension, abduction, adduction, internal rotation, and external rotation
- Weight shifting – progressing to balance exercises with double limb support balance activities to improve proprioception and weight acceptance
- Standing hip abduction and extension (no active hip abduction with hip abductor repairs)
- Sidelying leg raises leg in internal rotation (no active hip abduction with hip abductor repairs)
- Prone heel squeezes with hip extension
- Active range of motion without resistance (starting with short arc movements progressing to full arc)
- Start strengthening short external

	<p>rotators with isometric and short arc movements</p> <ul style="list-style-type: none"> • Stomach lying on elbows for gentle anterior hip stretch • A continuous passive motion machine may be used after microfracture procedures <p><small>[L] [SEP]</small>NOTE: Avoid straight leg raises as the long lever arm can cause significant forces across the anterior hip and is often irritating when performed in the first 6 weeks after surgery</p>
Cardiovascular	<ul style="list-style-type: none"> • Upper body circuit training or upper body ergometry (UBE)
Progression Criteria	<ul style="list-style-type: none"> • Normal gait without assistive device on level indoor surfaces with full weight bearing and minimal to no pain • Good leg control at low velocity of movement • Functional range of motion without pain

PHASE II (begin after meeting phase I criteria, time on crutches and limited range of motion varies with the procedure performed, about 4-6 weeks)

Appointments	<ul style="list-style-type: none"> • Rehabilitation based on patient progress, 1 to 2 times every 1 to 2 weeks
Rehabilitation Goals	<ul style="list-style-type: none"> • Regain and improve muscular strength • Progress off crutches for all surfaces and distances [SEP] • Single leg stand control • Good control and no pain with functional movements, including step up/down, squat, partial lunge
Precautions	<ul style="list-style-type: none"> • Post-activity soreness should resolve within 24 hours • No ballistic or forced stretching • Avoid post-activity swelling or muscle weakness • Be cautious with repetitive hip flexion activities, such as treadmill and Stairmaster • Patients undergoing microfracture continue the microfracture precautions • Regain and improve muscular strength • Progress off crutches for all surfaces and distances • Single leg stand control • Good control and no pain with functional

	<p>movements, including step up/down, squat, partial lunge</p>
<p>Suggested Therapeutic Exercises</p>	<ul style="list-style-type: none"> • Stationary bike • Gait and functional movement drills in the pool once portal sites are healed • Continue standing hip abduction and extension, double & single leg bridging, sidelying leg raises with leg in internal rotation and prone heel squeezes with hip extension • Non-impact hip and core strengthening – body boards, bridging (progressing from double to single leg), mini band drills, Swiss ball drills • Non-impact balance (progressing to single leg) and proprioceptive drills • Shuttle leg press • Quadriceps strengthening • Hip active range of motion using D1 and D2 patterns with proprioceptive neuromuscular facilitation • Stretching for patient specific muscle imbalances
<p>Cardiovascular Exercise</p>	<ul style="list-style-type: none"> • Non-impact endurance training; stationary bike, Nordic track, swimming, deep water run, cross trainer
<p>Progression Criteria</p>	<ul style="list-style-type: none"> • Normal gait on all surfaces • Ability to carry out functional movements without unloading affected leg or pain, while demonstrating

	<p>good control</p> <ul style="list-style-type: none"> • Single leg balance greater than 15 seconds
--	--

PHASE III (begin after meeting phase II criteria, about 10-12 weeks)

Appointments	<ul style="list-style-type: none"> • Rehabilitation based on patient progress, 1 to 2 times every 1 to 2 weeks
Rehabilitation Goals	<ul style="list-style-type: none"> • Improve muscular strength and endurance • Good control and no pain with sport and work specific movements, including impact activities
Precautions	<ul style="list-style-type: none"> • Post-activity soreness should resolve within 24 hours • No ballistic or forced stretching • Avoid post-activity swelling or muscle weakness • Be cautious with repetitive hip flexion activities, such as treadmill and Stairmaster • Patients undergoing microfracture continue the microfracture precautions
Suggested Therapeutic Exercise	<ul style="list-style-type: none"> • Multi-planar strength progression, including forward, lateral and diagonal lunges • Impact control exercises beginning 2 feet to 2 feet,

	<p>progressing from 1 foot to other and then 1 foot to same foot then progress from single plane drills to multi-plane drills</p> <ul style="list-style-type: none"> • Dynamic control exercise beginning with low velocity, single plane activities and progressing to higher velocity, multi-plane activities • May use agility ladder • Progress to running program once patient is able to demonstrate good single leg landing control in a repetitive fashion without pain • Begin sport specific drills once patient demonstrates good control with the impact control and multi-plane exercises and can tolerate running program without pain • Sport/work specific balance and proprioceptive drills • Hip and core strengthening • Stretching for patient specific muscle imbalances
<p>Cardiovascular Exercise</p>	<ul style="list-style-type: none"> • Replicate sport or work specific energy demands
<p>Return To Sport/Work Criteria</p>	<ul style="list-style-type: none"> • Normal gait on all surfaces • Dynamic neuromuscular control with multi-plane activities, without pain or swelling

REFERENCES

1. Enseki KR, Martin RL, Draovitch P, Kelly BT, Philippon MJ, Schenker ML. The hip joint: arthroscopic procedures and postoperative rehabilitation. *J Orthop Sports Phys Ther.* Jul 2006;36(7):516-525.
2. Larson, CM and Giveans. Arthroscopic management of femoroacetabular impingement: early outcomes measures. *Arthroscopy.* May 2008;24(5):540-546.
3. Schmerl M, Pollard H, Hoskins W. Labral injuries of the hip: a review of diagnosis and management. *J Manipulative Physiol Ther.* Oct 2005;28(8):632.
4. Stalzer S, Wahoff M, Scanlan M. Rehabilitation following hip arthroscopy. *Clin Sports Med.* Apr 2006;25(2):337- 357, x.
5. Standaert CJ, Manner PA and Herring SA. Expert Opinion and Controversies in Musculoskeletal and Sports Medicine: femoroacetabular impingement. *Arch Phys Med Rehabil.* May 2008;89:890-893.
- 6 Decker MJ, Torry MR, Anstett F, Giphart JE, Wahoff M and Philippon MJ. Gluteus Medius Muscle Activation During Hip Rehabilitation Exercises. Denver, Colorado. AAOSM Meeting July 9, 2009 – Research Presentation.